

**OFFICE OF THE MEDICAL EXAMINER
DISTRICT NINE
1401 Lucerne Terrace
Orlando, Florida 32806-2014**

REPORT OF EXAMINATION

DECEDENT: CAYLEE M. ANTHONY **CASE NUMBER:** ME 2008-001567

MANNER OF DEATH: HOMICIDE

IDENTIFIED BY: BASED ON NUCLEAR DNA COMPARISON DONE BY THE FBI
LABORATORY (SKELETAL SPECIMEN FOR IDENTIFICATION: RIGHT TIBIA)

AGE: AGE AT DISAPPEARANCE; 2 YEARS, 10 MONTHS

ANTHROPOLOGIC ESTIMATION OF AGE, 3 YEARS PLUS/MINUS 6 MONTHS

SEX: FEMALE **RACE:** WHITE **BIRTH DATE:** August 9, 2005

DATE OF DEATH: (FOUND) 12-11-08

DATE/TIME OF EXAMINATION: December 11, 2008, through December 23, 2008

EXAMINATION AND SUMMARY ANALYSIS PERFORMED BY:

Jan C. Garavaglia M.D.
Jan C. Garavaglia, MD, Chief Medical Examiner

Initial examination: Gary Lee Utz, MD, Deputy Chief Medical Examiner

Osteological examination: John Schultz, Ph.D., and Michael Warren, Ph.D., D, ABFA

Scene dispersal examination: John Schultz, Ph.D.

Toxicology examination: Bruce A. Goldberger, Ph.D., DABFT

CAUSE OF DEATH: **Homicide by undetermined means**

continued...

6440

FINDINGS

- I. Homicide by undetermined means
 - A. Completely skeletonized, approximately 3 year old child found in a wooded overgrown area
 - 1. Reportedly last seen alive 06-16-08
 - 2. Reported missing to law enforcement 07-15-08
 - B. Portion of skeletal remains intermixed with two plastic trash bags and a canvas laundry type bag
 - 1. Postmortem scattering of skeleton
 - a. Vertebrae found clustered in an area away from skull and bags
 - b. Clustering of other anatomic units were found in other locations
 - 2. Skeleton completely disarticulated with no soft tissue attached, and minimal adipocere found on several bones
 - 3. Small roots adhered to and growing into vertebral bodies
 - C. Several overlapping pieces of duct tape, over the anterior portion of the lower skull, including mandible and a portion of the maxilla
 - 1. Duct tape still attached to scalp hairs
 - 2. Mandible still in approximate anatomic position with no visible attached soft tissue beneath the duct tape
 - D. No antemortem trauma evident on the skeleton
 - E. Toxicology testing detected no drugs
 - 1. Specimens used for examination
 - a. Bone from left femur
 - b. Cancellous bone scrapings taken from the medullary cavity of the left femur
 - c. Hair removed for toxicology testing included both tied strands of hair and cut squares of hair from the hair mat
 - d. Soil removed from the hair mat
 - e. Saline washings of cranial cavity

TOXICOLOGY ANALYSIS: See laboratory report.

CONCLUSION/OPINION: As often is the case with a skeletonized individual, the exact cause of death cannot be determined with certainty. The manner of death is an opinion based on available information, including circumstances

ANTHONY, CAYLEE M.
ME 2008-001567
PAGE 3

surrounding the death, information from the scene, and examination of the skeletal remains.

The circumstances of death are that this toddler child, with no known medical history, was not reported missing to authorities for approximately 30 days. This child's remains were eventually found in a wooded, overgrown area, discarded with two trash bags and a laundry bag. Although there is no trauma evident on the skeleton, there is duct tape over the lower facial region still attached to head hair. This duct tape was clearly placed prior to decomposition, keeping the mandible in place.

The clustering of vertebrae at the scene separate from the location of the bags and skull indicate animal activity occurring at this location after decomposition started, but before complete disarticulation of the skeleton. This indicates the body was put in this location prior to complete skeletonization. The roots growing into the vertebrae and bags indicate that the body was placed there months prior to being found. There is nothing inconsistent with the body being placed there soon after the date of being last seen alive.

It is, thus, my opinion that, although the cause of death cannot be determined with certainty, the manner of death is homicide.

The examination of the remains of Caylee M. Anthony is performed pursuant to Florida Statute 406.11 by Jan C. Garavaglia, MD, Chief Medical Examiner, District Nine at the Orange County Medical Examiner facility, Orlando, Florida, from December 11, 2008, to conclusion December 23, 2008.

IDENTIFICATION: The skeletal remains were identified by nuclear DNA comparison done by the FBI DNA laboratory in Quantico, Virginia. The DNA from the skeleton was taken from the tibia.

SEQUENCE OF EVENTS:

Initial examination and separation of items which were received Thursday evening, 12-11-08, were done by Dr. Gary Utz, Deputy Chief Medical Examiner, and Dr. John Schultz, anthropologist, at the District 9 Medical Examiners Office. (See attached reports by Dr. Utz and Dr. Schultz.)

On 12-11-08, at the request of Dr. Jan C. Garavaglia, Chief Medical Examiner, Dr. John Schultz was asked to help assist with the recovery process at the scene.

On 12-12-08, at the request of law enforcement, duct tape was released to the FBI for analysis.

In addition, received from the Orange County Sheriff's Office from the scene were an ulna, radius, humerus, two femurs, a fibula, 15 ribs, a scapula, an ilium, two clavicles, two teeth, and two vertebrae, as well as an epiphysis and miscellaneous bones.

On 12-13-08, Dr. Jan Garavaglia, while at the scene, identified additional human bones received from the Orange County Sheriff's Office. They were numerous small bones, as well as a piece of pubic bone, a tibia, three more teeth, as well as approximately 20 either intact or portions of vertebrae, as well as three ribs and a fragment of rib.

Subsequent examination of skeleton and clothing was done at the office by Dr. Jan Garavaglia, Chief Medical Examiner, with anthropologist Dr. John Schultz, and Dr. Michael Warren, examining the skeleton. (See attached osteologic analysis.)

On 12-14-08, two more vertebrae and several miscellaneous bones and an ilium were received from the scene.

On 12-15-08, one rib was received.

On 12-16-08, small hand bones were received.

On 12-17-08, a rib bone and bone fragments were received.

On 12-18-08, small miscellaneous bones were recovered and received. Dr. Goldberger and Dr. Garavaglia removed specimens for toxicologic examination, including strands of head hair measuring approximately 6 inches in length which were tied at the proximal end. These were teased from the mat of head hair which was present initially underneath the skull. Also removed for toxicologic testing was a portion of the left femur, as well as, scrapings of cancellous bone from the medullary cavity of the left femur. Soil was taken from the hair mat and small rectangular sections of hair mat were removed. Saline washing of the cranial cavity was also collected.

EXAMINATION:

In summary, the initial examination was done by Dr. Gary Lee Utz and Dr. John Schultz and included separation of items present within a white body bag. Contained within a shroud was an intermingled mix of two black plastic large trash bags with yellow circular handles, a canvas style laundry bag, dirt, green and dried vegetative material, insects, pupae, multiple cloth letters, remnants of stitching with an attached garment tag, and a piece of stretchy synthetic paper/cloth, as well as human bones. Some of the bones were recovered intermixed with this material and some from within at least one of the black trash bags.

Vegetative material still present in the shroud upon my examination are leaves, roots, and vines, as well as other green and dried vegetative material, a slight amount of dried pupae, sandy dirt, spiders, and a few scattered silverfish.

Also found with the material are 10 gnarled, irregular fragments of black plastic consistent with coming from black plastic trash bags. There is also a piece of lighter gray synthetic material which is less than 1 inch in size. There is also a

small piece of yellow, thin plastic consistent with coming from a yellow handle of one of the black plastic trash bags.

Cloth Letters:

The cloth letters initially found within the vegetative material consist of four separate sets of lettering. One set of letters are 2 inches in height. They have pink, glittery substance on the anterior side of the letters and a pink discoloration on the back of the letters. The three letters of this size are "B," "I," and "G."

The second set of letters found in the leaf litter debris consists of seven letters, each measuring 1-1/2 inches in height. They also have the glittery appearance on the front and a pink discoloration on the back. They appear to spell the word, "T-R-O-U-B-L-E." The letters are not connected to each other.

The third set of letters are connected and consist of the word, "COMES." These letters are $\frac{3}{4}$ inch in height, and also have the glittery appearance on the front and the pink discoloration on the back.

The fourth set of letters are also attached and form the word, "SMALL." They are $\frac{3}{4}$ inches in height and also have a similar appearance, with the glitter on the front and pink on the back.

Stitching and Garment Tag:

The stitching found appears to be from the seams and hems of a shirt. The stitching is pink in color. In the region that would consist of stitching near the collar seam is a garment tag which states, "3 Toddler, 100% cotton, Made in El Salvador."

Laundry Bag:

The laundry bag received intermixed with the plastic bags has the appearance of an off-white to tan color. It has a stained canvas-texture type material on the outside with a smooth, coated material on the inside. There is an open loop at the top of the laundry bag, keeping it round, with what appears to be due to a metal ring which is seen on x-ray. This ring has a diameter of 16-1/2 inches. The height (depth) of the laundry bag is 24 inches. Also attached to the top of the laundry bag are long canvas strap loops which are approximately 21 inches in length each. There is no appreciable deterioration of the bag, which is still

intact. Stated on a tag attached to the top portion of the bag is "100% polyester." This tag also states that the brand name is "Whitney Design from Whitney Design, Inc." Also on this tag is a statement, "Today's Home Essential." There is fine silt and sand present in the bag, as well as dirt. There are thin roots growing on the outside of the bag which are intimately attached to the surface fabric. Present inside this laundry bag are two fragments of black, gnarled plastic consistent with the black trash bags which were found entangled with this laundry bag.

Trash Bags:

The two plastic bags that were intertwined with the laundry bag and the other assorted leaf and vegetative material consist of a cinched trash bag at least 36 inches in length (bag was left cinched), while the other is an untied bag approximately 40 inches in length. Both bags have a yellow plastic attached cinch tie. The one that is tied is tied with a single loop and two loose ends. Both bags have large defects, with gnarled, fragmented tearing with missing pieces of plastic from both bags. There are multiple roots extending through portions of the plastic bag. At least one of the roots is 10 cm in length and completely extends through the bag. The bags have a woody, outdoor odor with no smell of decomposition.

Blanket:

The baby blanket found intermixed with the plastic bags is discolored. It has stitching around its edges. Although the blanket is discolored and faded, a print of Winnie the Pooh is evident with Piglet riding on his back. The design is present on both sides of the blanket. Multiple fine roots appear to be growing completely through the blanket.

Diaper/Pull-Up Type Material:

Also received in the body bag mixed with this debris is a flap of somewhat rectangular shaped synthetic, stretchy, paper type material, measuring 6 x 6 inches. It has a stretchy, almost corrugated appearance. It is stained gray with attached rootlets at one end. Also attached to one of the corners of this rectangular shaped material is a purple colored, thin, stretchy ribbon type material. It appears slightly stretchier than the rectangular shaped synthetic material. This thin ribbon measures 9-1/2 inches in length and has a width of

7/8 inch, and has a purplish color. Overall this piece of material has the appearance of coming from a diaper or pull-up type item.

Received in a separate bag labeled, "1429 by pink flag" is a piece of rectangular shaped, flat material measuring 15 inches in length and 6-1/2 inches in width. On one side is an irregular paper-like material and on the opposite side is a smoother, slightly shinier appearance. Along one long edge there appears to be a hem. On the paper-appearing irregular side are blotches of color which are green and yellow, which appears to be an unidentifiable printed pattern on this material. Also attached are long, thin roots.

Shorts:

Received in a paper bag are partially decomposed multi-colored shorts which have pink, green and orange thin stripes and a pink button on the front of the waistband. The clothing tag has the brand, "Circo Brand." The tag also states, "100% cotton-24 months." There is an elastic waistband in the back of the shorts and a flat front. There are two pockets in the front and two pockets in the back. All of the pockets are empty. The shorts have multiple, irregular defects consistent with decomposition. They are also stained with dirt and slight vegetative material attached.

Skeletal Remains:

The skull was initially received in a separate paper bag with duct tape over the lower portion of the face, with the tape still attached to some of the scalp hair. A large portion of the scalp hair was in a mat under the skull. The mandible was still in its approximate anatomic location in spite of complete skeletonization. (See attached reports by Dr. Utz and Dr. Schultz.)

The remains were completely skeletonized, with no soft tissue, ligaments or tendons evident on any of the bones. Examination of the skeleton reveals an almost complete skeleton of a young child with only multiple small bones missing. The missing bones include small bones from the wrists and hands, as well as fingers and ankle, hyoid and patella. (See anthropology report.)

Examination of the skull reveals no evidence of antemortem trauma. The inner aspect of the cranial cavity is examined with light and reveals sandy dirt and an attached small incisor which is adhered to the inside of the calvarium with dirt. The mandible still has nine lower teeth attached with four teeth still present in

the maxilla. All of the teeth that were lost during decomposition were subsequently found at the scene, except for one incisor.

The mat of hair which was initially found beneath the skull with strands of hair extending across the calvarium and face consists of medium brown hair. Some strands of hair could be teased from the mat and were at least 6 to 7 inches in length. There are numerous small defects within this mat of hair, presumably from insect activity, and there are multiple small roots growing through the mat of hair.

Examination of the rest of the skeleton also reveals no evidence of antemortem trauma. X-rays also revealed no evidence of antemortem trauma. Several pieces of the skeleton have postmortem animal activity evident. There is no soft tissue present on any of the bones. There is a minimal amount of adipocere present and the bones have sandy, silty dirt on their surfaces, except for the skull.

A small rectangular piece of bone had been removed from the right tibia for the FBI for DNA analysis, and a fragment of bone was removed from the left femur for toxicology testing.

JCG:alm

INITIAL EXAMINATION:

INITIAL EXAMINATION PERFORMED BY:


Gary Lee Utz, MD, Deputy Chief Medical Examiner

Received Thursday, December 11, 2008, from the recovery site are the following items:

- 1) Body bag and shroud which contained garbage bags, a laundry bag, skeletal remains and debris
- 2) Paper bag with skull, attached hair, tape, and debris
- 3) Paper bag with clothing
- 4) Paper bag with fabric and leaf litter
- 5) Paper bags (4), each containing one long bone
- 6) Paper bag with 2 small bones

Item #1 consists of a jumbled mass of two disrupted black garbage bags with yellow handle ties, a cylindrical fabric laundry bag, leaf litter, vines, soil and debris. This material is received in a white shroud within a white body bag. Upon opening the shroud, a long bone is noted resting on the surface of the garbage bags. The entire contents of the shroud are photographed. Radiographs are obtained. The bags and associated leaf litter and debris with remains are soaked. The garbage bags and fabric bag are separated from the plant material. Nine (9) separately identifiable bones are recovered (2 additional small bones are later recovered after drying of the plant material). Also recovered are multiple fabric letters, remains of an apparent shirt, a roughly rectangular fragment of fabric, and a blanket. Each of these items is examined, photographed and allowed to dry. Later examination follows. Also in the bag are multiple live insects and puparia. The remaining contents and the bags themselves are allowed to dry and are examined later.

Item #2 consists of a paper bag containing a juvenile human skull, matted hair, tape and leaf litter. The skull is removed from the bag, photographed, and x-rays are obtained.

The calvarium is totally exposed and there is only a very small amount of adherent soil and leaf litter. No soft tissue remains. Multiple strands of medium brown straight hair extend over the calvarium in the sagittal and coronal planes. They are attached to a nest-like mass of matted hair which covers the basilar and lower posterior skull, including inferior portions of the mandible. Plant roots have grown into and over the surface of the hair mat. Attached to the hair and overlying the posterior mandible and maxilla are several pieces of overlapping gray tape. The tape has an open weave fabric backing and is delaminating. The tape is removed and allowed to dry. The matted hair is removed from the skull. Plant roots permeate the mat and there are multiple small roughly circular, irregular defects in the mat, suggestive of insect predation artifact. The hair is permitted to dry pending additional examination. Preliminary examination of the skull reveals no evidence of trauma.

Item #3 consists of a paper bag containing striped short pants. The attached tag indicates "Size 24 months." There is a small amount of soil and leaf litter attached to the pants. They are allowed to dry pending later examination.

Item #4 consists of a paper bag with a roughly rectangular paper-like fragment of fabric. There is a small amount of associated soil and leaf litter. The fabric is allowed to dry pending later examination.

Items #5 and #6 consist of 5 paper bags, 4 of which contain human long bones, and the 5th two small bones.

GLU/alm

REPORT OF OSTEOLOGICAL ANALYSIS

M.E. DISTRICT IN FLORIDA: 9 **M.E. CASE NUMBER: 08-1567**
ANTHROPOLOGY CASE NUMBER: UCF 2008-12A

REPORT SUBMITTED TO

Drs. Jan Garavaglia and Garry Utz
District 9 Office of the Medical Examiner
1401 Lucerne Terrace
Orlando, FL 32806
(407) 836-9400

REPORT SUBMITTED FROM

John J. Schultz, Ph.D.
Assistant Professor of Anthropology
Department of Anthropology
University of Central Florida
Orlando, FL 32816
(407) 823-4611 or 2271
jschultz@mail.ucf.edu

Michael W. Warren, Ph.D., D,ABFA
Associate Professor of Anthropology
Department of Anthropology
University of Florida
Gainesville, FL 32611
(352) 392-2253, extension 206
(352) 256-5734
mwarren@ufl.edu

BACKGROUND INFORMATION OF SKELETAL ANALYSIS

For recording purposes at the University of Central Florida, the number UCF 2008-12A was assigned to this case (2008-1567) from the District 9 Office of the Medical Examiner. The remains in question were located on December 11, 2008 in a heavily

wooded area on the south side of the 8900 block of Suburban Rd., Orlando, Orange County. The remains were scattered within a wooded area and were recovered by Orange County Sheriff's Office (OCSO) Forensic Unit starting on December 11, 2008 and ending on December 20, 2008. As the consulting anthropologist for the District Nine Medical Examiner's Office, Dr. Schultz provided an advisory role to the OCSO Crime Scene Unit throughout the recovery. On December 12 (full day) and 14 (afternoon), Dr. Schultz worked with the Crime Scene Investigators during the recovery, and he was in contact with Mrs. Susan Mears, Forensic Unit Supervisor, every day during the recovery via phone. In addition, Dr. Schultz traveled to the scene on a regular basis (except for December 13 and 20) to identify human bones, assess the progress of the recovery, and discuss search strategies for locating missing bones with Mrs. Mears. All non-human bones and suspicious materials that were located at the scene were identified as either non-bone or non-human by Dr. Schultz.

The remains are believed to be those of Caylee Anthony, a white (European ancestry) female born on August 9, 2005, who would have been approximately two months shy of three years of age when last seen alive by a credible eyewitness on June 16, 2008. Caylee has no known dental history, but has visited a pediatrician. No antemortem clinical radiographs were available for antemortem-postmortem radiographic comparison. We are not aware of a history of significant trauma or pathology noted in her medical records.

This consult was requested by Dr. Gary Utz (Deputy Chief Medical Examiner) and Dr. Jan Garavaglia (Chief Medical Examiner). We were asked to assist in identifying the decedent and examine the remains for evidence of trauma, and record evidence of taphonomic modifications.

SUMMARY OF THE ANALYSIS

Number of Individuals: - one
Sex: - undetermined
Ancestry: - undetermined
Age at Death: - 3 years \pm 6 months
Stature: - between 36.061 and 37.82 inches
Antemortem Conditions: - no significant antmortem conditions were noted
Distinguishing Features: - none noted
Perimortem Trauma: - no evidence of perimortem trauma was noted
Postmortem Modifications: - of note is animal damage
Time Since Death: - see separate report to be submitted by Dr. John Schultz
Identification: - consistent with the age of **Caylee Anthony** when she was last seen alive

CONDITION OF REMAINS AND PROCESSING

The unidentified remains were analyzed at the District 9 Medical Examiner's Office on December 11 (preliminary), 13 (preliminary), 15, 16, 18, 19, 20, and 23. The skeletal remains were completely devoid of any soft tissues, including ligaments and cartilage. No odor of decomposition was detected. The remains were prepared for examination by brushing off adhered dirt with a soft bristled brush as needed. Non-sterile examination gloves were worn when handling the remains.

On December 11, Dr. Utz and Dr. Schultz separated a light colored laundry bag from two black garbage bags with yellow pull ties. The two black bags were torn in multiple places and intermingled, and were partially within the laundry bag. The laundry bag contained a rigid metal rim, as seen on x-ray, around the opening. The black bags were positioned on top of the metal rim while a fold of the laundry bag was visible overlaying the top of the garbage bags. An unfused tibial diaphysis was found directly on top of the mass consisting of the laundry bag and jumbled black bags. A number of human bones were located mixed with the leaf debris from within the bags. In addition, although the black bags were torn, two hand bones were removed directly from the black bags. In terms of the bones recovered from the mass of bags, a right scapula, five finger bones, a proximal humeral epiphysis, a primary ossification center, and a proximal tibial epiphysis were recovered. In addition, two small ossification centers were located on December 15 after sorting through the dried debris.

On December 11 Dr. Utz and Dr. Schultz removed the skull from the brown paper collection bag by tearing the corners of the bag to expose the skull. A hair mat was noted on the base of the skull and grayish colored tape was noted covering the mouth and nasal aperture areas. The tape remained in place because it was adhered to the hair of the skull. In addition, the mandible was still retained underneath the base of the cranium positioned slightly posterior. Dr. Utz removed the tape and the hair matt for analysis. At that time, Dr. Schultz provided a preliminary age based on the completed erupted primary dentition and the developing secondary dentition that was approximately between 2.5 and 3 years of age based on the dental eruption and development chart by Ubelaker (1989).

Opinion: Considering the dispersal of the skeletal remains, it would not be expected to find the mandible in this position unless something affixed the mandible in this position prior to decomposition and the hair matting forming. In skeletal cases involving surface depositions, the mandible and cranium are normally found disarticulated because there is nothing to hold the mandible in place after the soft tissues decomposes. Based on the position of the tape and mandible, it can be inferred that the mandible remained in this position because the tape held it in place prior to the hair forming into a matt on the base of the skull.

INVENTORY AND NUMBER OF INDIVIDUALS

There was no duplication of skeletal elements and all of the skeletal remains are consistent in size, morphology, texture, color, and age. Thus, only one individual is present.

A significant number of skeletal elements were recovered – see Appendix for a complete inventory. The following complete or partial elements were represented: all long bone diaphyses, scapulae, clavicles, os coxae, and sternum. All cervical, thoracic, and lumbar vertebrae were represented by either the neural arch, centrum, or both. One lateral element of the sacrum, but no coccygeal elements, were recovered. Twenty one ribs were represented, as well as several tarsal, carpals, metacarpals, metatarsals, and hand/foot phalanges.

Elements not recovered included small bones representing the wrist, hand (only one metacarpal was not recovered), fingers, ankle, foot, wrist, hyoid, and patellae. In addition, only one tooth was lost postmortem (upper left lateral incisor).

SEX

Various studies addressing the possibility of determining sex from an immature skeleton have high rates of error. Most anthropologists agree that attempts to determine sex from the skeleton in infants and children constitute poor forensic practice.

AGE AT DEATH

The remains are those of a child. All epiphyses of the long bones remain unfused. The sphenoid-occipital synchondrosis is unfused, and the sutura intra-occipitalis anterior remains partially fused. All erupted dentition is deciduous. Age at death is estimated using two principal methods, long bone diaphyseal lengths and dental crown-root development and emergence.

Long Bones: The long bone lengths are:

Bone	Diaphyseal length
Right humerus	139 mm.
Left humerus	138 mm.
Right radius	110 mm.
Left radius	109 mm.
Right ulna	122 mm.
Left ulna	120 mm.
Right tibia	166 mm.
Right fibula	163 mm.
Left fibula	162 mm.

Mean ages for female long bone length are provided below (Maresh, 1970).

Bone	Age	Mean length \pm SD
Humerus	@ 2.5 years	136.9 mm. \pm 6.1 mm.
	@ 3.0 years	145.3 mm. \pm 6.7 mm.
Radius	@ 3.0 years	107.7 mm. \pm 5.2 mm.
	@ 3.5 years	113.8 mm. \pm 5.5 mm.
Ulna	@ 3.0 years	120.6 mm. \pm 5.4 mm.
	@ 3.5 years	127.2 mm. \pm 5.7 mm.
Tibia	@ 3.0 years	173.1 mm. \pm 9.9 mm.
	@ 3.5 years	183.7 mm. \pm 10.5 mm.
Fibula	@ 3.0 years	159.4 mm. \pm 7.9 mm.
	@ 3.5 years	169.6 mm. \pm 8.3 mm.

Note: *n* for ulna lengths for 2.5 year-olds is 82; *n* for 3.0 year-olds is 79; *n* for 3.5 year-olds is 78. The sample size for the other long bones is comparable. The data from Maresh (1970) are based on radiographic long bones lengths of white, middle-class, well-nourished children.

The recorded long bone length of the right humerus is 139 mm., which is greater than the mean length for 2.5 year-olds and less than the mean length for 3.0 years.

The recorded long bone length of the right radius is 110 mm., which is greater than the mean length for 3.0 year-olds and less than the mean length for 3.5 years.

The recorded long bone length of the right ulna is 122 mm., which is greater than the mean length for 3.0 year-olds and less than the mean length for 3.0 years.

The recorded long bone length of the right humerus is 139 mm., which is greater than the mean length for 2.5 year-olds and less than the mean length for 3.5 years.

The recorded long bone length of the right fibula is 163 mm., which is greater than the mean length for 3.0 year-olds and less than the mean length for 3.5 years.

Considering the above data, age at death based on long bone length is between 2.5 years and 3.5 years, but towards the upper part of this range. These data are derived from growth studies beginning in the 1950s, so some secular change in the direction of precociousness might be anticipated (Maresh, 1970).

Hoffman (1979) shows long bone lengths relative to age in graphical form, but supplies no formulae to directly calculate age. All of the above lengths correspond to around age 3, or slightly older, on his respective figures.

Dentition: Radiographs were taken and recorded using the “Dexis” system housed in the District 9 Office of the Medical Examiner.

The first molar crown-root development is in stage “D” (Demirjian and Levesque, 1980). This study has too few individuals at this stage to provide statistical meaning. However, stage “E” offers a median age of attainment for girls as 3.7 years, and boys as 4.1 years. At this stage the crown of M_1 is fully developed and the roots are beginning to emerge. Earliest crown completion and beginning root formation for the first mandibular molar, according to Garn *et al.* (1958), is 4.0 years. The radiographs of this individual show little to no root development, and so the decedent is therefore younger than those ages (see Figure 1). The crown of M_2 has not begun to form, or was small and lost through the aperture in the alveolar margin. Demirjian and Levesque (1980) report the median age for beginning development of the second mandibular molar is 3.5 years, and does not vary between girls and boys. Likewise, Moorees *et al.* (1963) report that the second molar begins development at around age 3 years.

The canine is in stage “D” (Demirjian and Levesque, 1980), indicating a median age of 2.9 years for girls and 3.3 years for boys (see Figure 2).

The lateral dental radiographs compare most favorably with the 3 year-old (± 12 months) standard published by Ubelaker (1978), and is most certainly between the 2 year-old and 4 year-old standards. It should be noted that this formation and eruption sequence is derived from a sex-pooled sample of Native Americans. When compared with the study by Schour and Massler (1942), a pooled sample of “white” children, the lateral radiographs fall within the mean standards for 2 years ± 6 months and 3 years ± 6 months. If the decedent is a female, it would be advisable to add approximately 6 months to this estimate, yielding an age estimate interval of 3 to 4 years.

Earliest crown completion and beginning root formation for the first mandibular molar, according to Garn *et al.* (1958), is 4.0 years. Again, this decedent’s molars display little to no root development, indicating an age of less than 4 years.




Figure 1: The first permanent mandibular molar (tooth #19) has a near complete crown, and little to no root development. The crypt for M_2 is open at the superior alveolar margin, so the presence or absence of a crown bud is unknown.




Figure 2: The mandibular canine (tooth #22) is in stage “D” (Demirjian and Levesque, 1980).

ANCESTRY

Estimation of ancestry is best achieved by non-metric and metric analyses of adult crania, particularly the mid-facial skeleton. Estimation of ancestry from the skeleton of a 3 year-old child is problematic and should be avoided in most cases.

STATURE

Long bone measurements in fetuses and adults may be used to determine crown-heel length and stature, respectively. The long bone lengths of infants and children have traditionally been regressed directly onto age and do not provide an estimate of living stature. The latest attempt at determination of stature in juveniles was by Smith (2007), who provided the following formulae for stature estimation based on a pooled sample of 31 boys and 36 girls:

Slope	y-intercept	Standard Error
0.4658 (hum)	+ 27.053	± 3.00 cm.
0.6229 (rad)	+ 27.500	± 3.16 cm.
0.5898 (ulna)	+ 23.742	± 2.91 cm.
0.3519 (tibia)	+ 38.614	± 2.24 cm.
0.3620 (fib)	+ 37.273	± 2.24 cm.

These formulae calculate the following estimations of stature for this case:

- 91.799 cm. \pm 3.00 cm., based on maximum length of the right humerus.
- 96.019 cm. \pm 3.16 cm., based on maximum length of the right radius.
- 95.697 cm. \pm 2.91 cm., based on maximum length of the right ulna.
- 97.029 cm. \pm 2.24 cm., based on maximum length of the right tibia.
- 96.279 cm. \pm 2.24 cm., based on maximum length of the right fibula.

The range of these estimates is between 36.061 inches and 37.82 inches. We would caution that these formulae are relatively new and untested by both authors of this report.

ANTEMORTEM TRAUMA AND PATHOLOGY

All skeletal elements were radiographed and examined grossly and microscopically for traumatic or pathological lesions. No evidence for significant antemortem pathology or healed trauma is noted. Bone quality is good and there are no signs of arrested growth in the long bone metaphyses. Areas of active bone near the ends of the metaphyses of some of the long bones are normal for growing children. There is no evidence of subperiosteal hemorrhage along the shafts of the long bones. The posterior half of the sagittal suture appears to be in the beginning stages of premature synostosis.

DISTINGUISHING FEATURES

No distinguishing features were noted on the remains available for analysis.

PERIMORTEM TRAUMA

There is no evidence of perimortem trauma to the skeletal remains available based on gross, microscopic, and radiographic analysis.

POSTMORTEM MODIFICATIONS

A number of postmortem modifications were noted to the remains available for analysis.

- Many of the skeletal elements exhibit slight soil staining and adhered soil and organic material.
- Minimal adipocere formation was noted on the left iliac blade, proximal left femur, a number of hand phalanges, and several vertebral elements.

- Remnants of light colored fabric were noted on the anterior aspect of the right scapula and the proximal-anterior aspect of the right humerus. The material was removed for possible analysis.
- The distal metaphysis of the left tibia sustained postmortem damage to the distal end. The margin was ragged in appearance and the margin and cancellous bone of the metaphysis exhibited a lighter color.
- Animal damage was noted as chewing with punctures, pits, and ragged borders on the proximal ends of the both femora (the right femora also exhibited a number of fractures due to animal chewing), the sternal end of the right clavicle, the head of the left 10th rib, the left 8th rib (only a small aspect of the head remained), the base of the right second metatarsal and the inferior aspect of the left ilium that includes the acetabular portion.
- Multiple minute rootlets have grown into and around multiple vertebral centra.
- There is a pupal casing adhering to the right scapula on the anterior surface at the superior angle.
- Some slight to moderate erosion is noted, particularly on elements without thick cortices, including the vertebral bodies, carpals, tarsals, and secondary ossification centers.

TIME SINCE DEATH

See separate report that will be submitted by Dr. John Schultz discussing time since death and dispersal of the skeletal remains.

IDENTIFICATION

Determination of sex and ancestry is unreliable based on examination of infant skeletal remains. The estimated age at death of 3 years \pm 6 months is consistent with the age of Caylee Anthony at the time of her disappearance and up to the time of the discovery of the remains.

REFERENCES CITED

Garn SM, Lewis AB, Koski K, Polacheck DL (1958) The sex difference in tooth calcification. *Journal of Dental Research* 37: 561-567.

Demirjian A, and Levesque G-Y (1980) Sexual differences in dental development and prediction of emergence. *Journal of Dental Research* 59(7):1110-1122.

Hoffman JM (1979) Age estimations from diaphyseal lengths: Two months to twelve years. *Journal of Forensic Science* 24(2): 461-469.

Maresh MM (1970) Measurements from Radiographs. In: McCammon RW (ed.) *Human Growth and Development*. Springfield, Ill., Charles C. Thomas, pp. 157-200.

Moorees CF, Fanning EA, and Hunt EE (1963) Age variation of formation stages for ten permanent teeth. *Journal of Dental Research* 42(6): 1490-1502.

Schour I and Massler M (1941) The development of human dentition. *Journal of the American Dental Association* 28:1153.


Smith SL. (2007) Stature estimation of 3-10-year old children from long bone lengths. *Journal of Forensic Science* 52(3): 538-546.

Ubelaker D (1989) *Human Skeletal Remains: Excavation, Analysis, Interpretation*, 2nd edition. Washington, D.C., Taraxacum Press.


APPENDED MATERIAL

Inventory, pages 11-13

Respectfully completed and submitted on this 23rd day of December, 2008.



John J. Schultz, Ph.D.
Assistant Professor of Anthropology
University of Central Florida



Michael Warren, Ph.D., D,ABFA
Associate Professor of Anthropology
University of Florida

Appendix - Inventory

<i>Bone</i>	<i>Element</i>	<i>Right</i>	<i>Left</i>	<i>Comments</i>
-------------	----------------	--------------	-------------	-----------------

Appendicular Skeleton

UPPER LIMBS				
Clavicle	Body	✓	✓	
	Proximal epiphysis			
Scapula	Body	✓	✓	
	Coracoid process	✓		
	Ventral border			
	Inferior angle			
Humerus	Diaphysis	✓	✓	
	Proximal epiphysis	✓		
	Distal epiphysis			
	Medial epicondyle			
Ulna	Diaphysis	✓	✓	
	Proximal epiphysis			
	Distal epiphysis			
Radius	Diaphysis	✓	✓	
	Proximal epiphysis			
	Distal epiphysis		✓	

HANDS				
Carpals	Body	<u>2</u> of 16		
Metacarpals	Body	<u>9</u> of 10		Missing MC4 on right
Phal. Prox.	Primary center	<u>9</u> of 10		Missing either L or R 5 th proximal phalange
Phal. Interm.	Primary center	<u>7</u> of 9		One epiphysis recovered, most likely from a prox. phalange
Phal. Distal	Primary center	<u>0</u> of 10		No distal phalanges recovered

LOWER LIMBS				
Os Coxa	Ilium	✓	✓	
	Ischium			
	Pubis	✓		
	Iliac crest			
	Ischial tuberosity			
Femur	Diaphysis	✓	✓	
	Proximal epiphysis			
	Greater trochanter			
	Lesser trochanter			
Tibia	Diaphysis	✓	✓	
	Proximal epiphysis			
	Distal epiphysis		✓	
Fibula	Diaphysis	✓	✓	
	Proximal epiphysis			
	Distal epiphysis			
Patella	Body			

FEET				
Calcaneus	Body	✓		
	Epiphysis			
Talus	Body	✓		
Other tarsals	Body	3 of 5		Primary centers do not yet have morphology that permits ident.
Metatarsals	Body	<u>1</u> of 5	<u>5</u> of 5	Left is a MT2
	Epiphysis			
Phalanges	Body			
	Epiphysis			

Axial Skeleton

Cervical				
Atlas	Lateral mass	✓	✓	No ant. arch recovered
Axis	Lateral masses	✓	✓	

	Dens	✓	
	Inferior centrum	✓	
C3 – C6	Body	<u>3</u> of 4	C3 missing centrum
	Neural arch	4 of 4	
	Spinous process	__ of 4	
	Transverse process	__ of 4	
C7	Body	✓	
	Neural arch	✓	
	Spinous process		
	Transverse process		

Thoracic

T1 – T11	Body	<u>6</u> of 12	
	Neural arch	<u>12</u> of 12	
	Spinous process	__ of 11	
	Transverse process	__/11	__/11

Lumbar

L1 – L5	Body	<u>4</u> of 5	L2-L5 neural arch and centra are in process of fusing
	Neural arch	<u>5</u> of 5	
	Spinous process	__ of 5	
	Transverse process	__/5	

Sacrum

	Body	__ of 5	
	Lateral ant. costal element	✓	__/3
	Lateral epiphyses	__/2	__/2

Coccyx

	Segments	__ of 4	
--	----------	---------	--

Thorax

Sternum	Manubrium			
	Corpus sterni	1 of var.		
	Xiphoid			
Ribs		2-12	1-10 #8 fragment of approx. 2.5 cm of vertebral end	Epiphyses for the heads and tubercles are not formed and/or recovered for all ribs.



REPORT OF SKELETAL DISPERSAL AT SCENE

M.E. DISTRICT IN FLORIDA: 9
ANTHROPOLOGY CASE NUMBER: UCF 2008-12A

M.E. CASE NUMBER: 08-1567

REPORT SUBMITTED TO

Dr. Jan Garavaglia
District Nine Office of the Medical Examiner
1401 Lucerne Terrace
Orlando, FL 32806
(407) 836-9400

REPORT SUBMITTED FROM

John J. Schultz, Ph.D.
Assistant Professor of Anthropology
Department of Anthropology
University of Central Florida
Orlando, FL 32816
(407) 823-1180
jschultz@mail.ucf.edu

BACKGROUND INFORMATION OF SCENE PARTICIPATION

For recording purposes at the University of Central Florida, the number UCF 2008-12A was assigned to this case (2008-1567) from the District Nine Office of the Medical Examiner. The remains of Caylee Anthony were located on 11 December 2008 in a heavily wooded area on the south side of the 8900 block of Suburban Drive, Orlando, Orange County. The remains were scattered within a wooded area and were recovered by the Orange County Sheriff's Office (OCSO) Forensic Unit starting on 11 December 2008 and ending on 20 December 2008. As the consulting anthropologist for the District Nine Medical Examiner's Office, Dr. Schultz provided an advisory role to the OCSO Forensic Unit throughout the recovery. On 12 (full day) and 14 (afternoon) December 2008, Dr. Schultz worked with the Forensic Unit during the recovery, and was in contact with Mrs. Susan Mears, Forensic Unit Supervisor, every day during the recovery

via phone. In addition, Dr. Schultz traveled to the scene on a regular basis (except for 13 and 20 December 2008) to identify human bones, assess the progress of the recovery, and discuss search strategies for locating missing bones with Mrs. Mears.

Dr. Jan Garavaglia (Chief Medical Examiner) requested a scene report that discussed dispersal of the skeleton and time since death.

DISPERSAL PATTERN OF SKELETAL ELEMENTS

In order to interpret the pattern of disarticulation and dispersal of the skeleton, a map of the site was created indicating the areas where the bones were located *in situ*. Bones that were located while sifting were not considered. A Specific Purpose Survey topographic map of the scene located at Suburban Drive, Section 13, Township 23 South, Range 30 East was created by personnel from Allen & Company. A Leica Scan Station 2 with Cyclone software was used in the field for processing the data points collected for the entire site to create the topographic map. Mr. Ronald Murdock, Forensic Unit Supervisor for OCSO, used a Leica TCR307 total station and a Sokkia SDR33 data collector to collect point data for each of the flags that were used to mark the location of either a single bone or bone parts, or a concentration of bones. I then identified nine bone locales or Areas of bones that encompassed the point data collected by Mr. Murdock to show groupings of bones or bone parts that were then incorporated on the topographic Specific Purpose Survey map of the scene as a layer by personnel from Allen & Company (Figure 1 in Appendix).

The shaded Areas in Figure 1 designate nine bone locales starting with Area A and ending with Area I. Below is a brief description of the major bones located within each Area. Refer to Table 1 in the Appendix for a detailed list of the bones that were located in each of the nine Areas.

- Area A included the primary decomposition site and may represent the initial dump site. This is the location where the skull, black plastic bags, canvas bag, and bones were located and recovered on 11 December 2008. Bones that were located in this area during the recovery include teeth, arm bones, wrist and hand bones, lower leg bones, ankle bones, and toe bones.
- Area B only included the left humerus diaphysis.
- Area C only included the left tibia diaphysis.
- Area D only included the right second metatarsal that sustained animal damage.
- Area E only included a small hand bone.
- Area F included both femoral diaphyses with carnivore damage, the right and left unfused ilium segment for both os coxae with carnivore damage to the left ilium, right and left clavicles, two ribs, and a half neural arch of C1.
- Area G included two ribs, L5, and an unfused element of S1.

- Area H included 9 ribs, a left scapula, and a half neural arch of C1
- Area I included four ribs and unfused segments representing 20 vertebrae.

Since the bones of the skeleton were found scattered throughout the site, interpretation of the pattern of dispersal can indicate if the skeleton was dispersed during the early stages of decomposition, prior to complete skeletonization. The pattern of dispersal and disarticulation of the skeletal remains is consistent with dumping the body into the woods prior to significant decay involving disarticulation of major anatomical units. For example, when bones of the same anatomical region, referred to as body units, are discovered in close proximity, they were likely transported as connected body units when soft tissue was still retained and holding the bones together (Haglund, 1997). Conversely, Haglund (1997) asserts that when the scatter pattern consists of single bones or a mix of bones representing different body units, transportation of individual bones occurred after decomposition/disarticulation was complete.

The body most likely was dumped in the woods during the initial stages of decomposition. Postmortem damage to multiple bones indicated that small animals scattered parts of the skeleton. The association of the skull with numerous hand and foot bones, arm bones, lower leg bones, and ankle and foot bones, is consistent with Area A being the primary decomposition site and possibly the dump site. For example, the association of loose maxilla teeth that were recovered in Area A with the skull is consistent with the skull decomposing in the area where it was located.

Bones of the trunk including the ribs, vertebrae, clavicles, parts of both os coxae, and both femora were located away from the body at the secondary decomposition sites (Areas F, G, H and I). Therefore, it would be expected that the trunk was dragged away from the primary decompositional site (Area A) by animals when the bones of the trunk and femoral diaphyses were still articulated or held together by soft tissues during the early stages of decomposition. The bones were then scattered to a number of secondary decomposition sites (Areas F, G, H, and I). For example, both femora and parts of the pelvis were located in Area F, and both femoral diaphyses were located together lying side-by-side (refer to picture numbers 6137, 6138, 6139, 6141, and 6142 from OCSO dated 12 December 2008). Locating the two femoral diaphyses in close proximity to one another with parts of the pelvis indicated that they were dragged to this area while still articulated, and then were damaged by animal chewing. In addition, unfused segments representing 20 vertebrae were located in the small Area I. This pattern is consistent with a large segment of the vertebral column being transported prior to disarticulation.

Area D only included the right second metatarsal that sustained animal damage and was the only bone from the right foot that was recovered. This Area represented the furthest extent that any bones were located moving away from Area A in a somewhat westerly direction.

TIME SINCE DEATH

Providing an estimate for time since death for the remains of Caylee Anthony included evaluating multiple lines of evidence that were gleaned from the recovery. Many small fibrous roots were located growing in a number of the bones including multiple vertebral bodies. The Botany Report dated 9 February 2009 that Dr. David Hall provided to Detective Yuri Mellich from OCSO, listed periods of time it would take for root growth found in the bones. Dr. Hall indicated that on 23 December 2008 and on 4 February 2009 he examined photographs of roots growing into the bones and determined a minimum period of approximately four months for the largest roots. It is important to note that the bones would first need to be disarticulated, completely skeletonized, and then stabilized for roots to adhere to and grow into the bones.

The taphonomy of the skeleton at the site is consistent with the minimum period of time for the root growth into bone that was provided by Dr. Hall as well as the time needed for skeletonization and stabilization of the bones prior to root growth. The following taphonomic changes will be discussed in more detail:

- Dispersal and burial of the left unfused ilium
- Rate of soft tissue decomposition and bone erosion
- Bones located under seasonal leaf fall

Dispersal and Burial of the Left Unfused Ilium

The association of clusters of anatomical units discussed above is consistent with the body being dispersed when soft tissue was still present and holding articulated bones together at the joints. Furthermore, the association of clusters of anatomical units demonstrates that fluvial transport was not a major factor with scattering of the remains. Although the overgrown nature of the wooded area would most likely have inhibited water from transporting the remains throughout the site, there was most likely some minimal movement of the bones by the water associated with seasonal summer storms. For example, the left unfused ilium of the os coxa was found mostly buried in the muck partially under the trunk of a palmetto bush (refer to picture numbers 6567 through 6572 from OCSO dated 14 December 2008). After the bone had been dispersed by carnivores as part of the trunk and deposited in Area F, the bone was mostly buried in the muck due to the movement of the water associated with seasonal summer storms.

Rate of Soft Tissue Decomposition and Bone Erosion

Overall, the bones were free of soft tissue, odor, and any evidence of recent death. There was no soft tissue remnants adhered to the bones and the bones were not greasy. Many of the skeletal elements exhibited slight soil staining with adhered soil and organic material. Also, slight to

moderate erosion was noted, particularly on elements without thick cortices, including the vertebral bodies, carpals, tarsals, and secondary ossification centers. In addition, minimal adipocere formation that is consistent with a moist environment was noted on the left iliac blade, proximal left femur, a number of hand phalanges, and several vertebral elements.

During the hot and rainy summer months in Florida (June, July and August), bodies will decompose rather quickly and can become skeletonized in less than a month. This estimate is supported through extensive human decomposition research at the Anthropology Research Facility that is located at the University of Tennessee in Knoxville. According to Mann et al. (1990; 105) when referring to warm or hot weather, "it usually takes between two and four weeks for a body to become nearly or completely skeletonized." Bass (1997; 181-182) further stated that "a body in Tennessee in July and August can go from what you and I know to a complete skeleton in two weeks." It is important to note that the decomposition research at the Anthropology Research Facility is primarily with larger adult bodies. Furthermore, Stewart (1979; 71-72) also supports that a body can be completely skeletonized by the end of two weeks when he provides a case involving a 12.5 year old female from Mississippi that was missing for ten days in August and was almost completely skeletonized.

The mean monthly temperature of the three summer months for June, July, and August in Orlando is 82°, which is hotter than the mean monthly temperature for Knoxville, TN and similar to Hattiesburg, MS (Table 2). It can be inferred that decay rates in the Orlando area should be faster than Knoxville, TN and similar to Hattiesburg, MS. It would be expected that decomposition of a small child in Florida that is deposited in an outdoor environment during the summer months would have occurred in less than a month and most likely within two weeks. Therefore, the body must have been dumped at the site during the early stages of decay prior to disarticulation of anatomical units.

Table 2. The average monthly temperature for the three summer months of 2008 from Weather Underground (<http://www.wunderground.com>)

Month	Knoxville, TN	Orlando, FL	Hattiesburg*, MS
June	77	82	82
July	78	82	84
August	77	82	81

*Since the Mississippi city for the case was not provided by Stewart (1979), the inland city of Hattiesburg was arbitrarily chosen to make a comparison with Orlando.

Seasonal Leaf Fall

Other than a number of bones that were located when the bags were removed, the majority of the bones were located under the leaf layer and many were in contact with the muck. In other words, the bones had to have been decomposed and scattered prior to the leaves falling and covering up

the bones during the fall season of 2008. According to Dr. David Hall (personal communication 12 January 2009; approximately 12:00-12:30 p.m.) there were a number of red maples in the area which would have produced a high leaf fall during autumn. Dr. Hall stated that the leaf fall would definitely occur by November and possibly as early as October depending on the temperature.

CONCLUSION/OPINION

The overall pattern of skeletal dispersal is consistent with the body of Caylee Anthony being dumped into the woods at the scene located on Suburban Drive during the early stages of decay, before significant disarticulation of anatomical units occurred. Animals then scattered the remains, including moving the trunk with the femora attached as a unit. The taphonomy of the skeleton at the site such as complete skeletonization with slightly eroded bone, minimal adipocere development on a number of bones, bones dispersed as anatomical units, bones located under leaf fall, adhered roots growing into a number of bones, and a left unfused ilium located almost completely buried in the muck is consistent with a time since death of multiple months. However, considering the environment where the remains were located, a time since death of approximately six months would not be inconsistent with the taphonomy of the skeleton.

APPENDED MATERIAL

Literature Cited, page 7

Table 1, pages 8-9

Figure 1, Specific Purpose Survey map created by Allen & Company, page 10

Respectfully completed and submitted on this 15th day of May, 2009.



John J. Schultz, Ph.D.
Assistant Professor of Anthropology
University of Central Florida

LITERATURE CITED

Bass WM. 1997. Outdoor decomposition rates in Tennessee. In: Haglund WD and Sorg MH, editors. Forensic taphonomy: the postmortem fate of human remains. Boca Raton, FL: CRC Press. p. 181-185.

Haglund WD. 1997. Scattered skeletal human remains: search strategy consideration for locating missing teeth. In: Haglund WD and Sorg MH, editors. Forensic taphonomy: the postmortem fate of human remains. Boca Raton, FL: CRC Press. p. 383-394.

Mann RW, Bass WM, Meadows L. 1990. Time since death and decomposition of the human body: variables and observation in case and experimental field studies. Journal of Forensic Sciences 35:103-111.

Stewart TD 1979. Essentials of forensic anthropology. Springfield, IL: Charles C. Thomas.

Table 1. Bone and bone parts located within each of the nine areas (flag numbers provided by Mr. Ronald Murdock)

Area	Flag Number	Bone or Part of Bone
A	None	mass of black bags, canvas bag, tibial diaphysis, right scapula, five finger bones, proximal humeral epiphysis, primary ossification center, proximal tibial epiphysis, and two small ossification centers
A	None	skull
A	1*	ulna diaphysis
A	1A**	ulna diaphysis, radius diaphysis, 8 small hand and wrist bones
A	2*	right fibula diaphysis
A	2A**	small hand bone
A	3*	right humerus diaphysis
A	3A**	two small hand bones
A	4*	small hand bone
A	4A**	two maxilla teeth
A	5*	small hand bone
A	5A**	small hand bone
A	6*	radius diaphysis
A	6A**	seven small hand bones
A	7	epiphysis
A	25	small hand bone
A	26	left fibula diaphysis and 11 left ankle and foot bones
A	29	two maxilla teeth
A	38	small hand bone
B	24	left humerus diaphysis
C	41	left tibia diaphysis
D	46	right second metatarsal
E	45	small hand bone
F	8	right unfused ilium
F	16	clavicle
F	17	rib
F	18	right and left femoral diaphysis with carnivore damage
F	22	clavicle
F	27	rib
F	28	½ neural arch of C1
F	42	left unfused ilium
G	19	rib
G	20	L5, sacral S1 unfused lateral element
G	21	rib

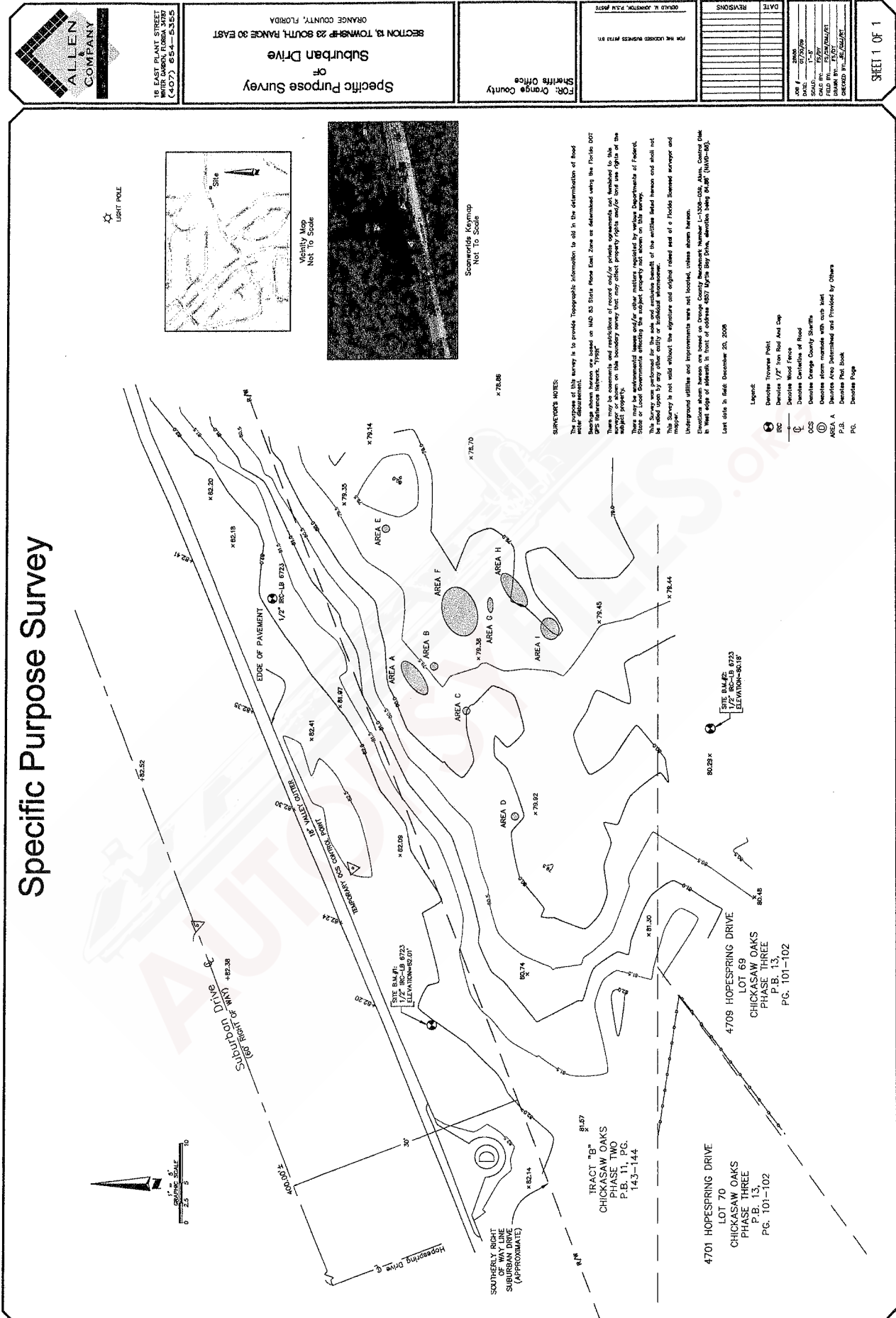
*Collected on 11 December 2008

** Collected on 12 December 2008

Table 1 (continued)

H	9	rib
H	10	2 ribs, ½ neural arch of C1
H	11	rib
H	12	rib
H	13	2 ribs, left scapula
H	14	rib
H	15	rib
I	30	rib, rib fragment with carnivore damage
I	35	2 ribs, unfused portions representing 7 vertebrae
I	36	unfused portions representing 10 vertebrae including C2 (½ neural arch, dens, and centrum present)
I	37	2 vertebrae
I	39	½ neural arch of C2
I	40	vertebra

Specific Purpose Survey



18 EAST PLANT STREET
MILWAUKEE, WISCONSIN 53202
TEL: 414.224.3333




SECTION 13, TOWNSHIP 23 SOUTH, RANGE 30 EAST
Suburban Drive
Specific Purpose Survey
Sherriff's Office
FOR: Orange County

DATE: 02/02/09
JOB # 090209
DRAWN BY: L.S.
CHECKED BY: J.W./J.T.
SCALE: AS SHOWN
DATE PLOTTED: 02/02/09

FOR THE UNDEVELOPED AREAS SHOWN BY THIS SURVEY

DATE	REVISIONS

SHEET 1 OF 1



SURVEYOR'S NOTES:
The purpose of this survey is to provide Topographic Information to aid in the determination of Flood Hazard Areas based on MAD 53 State Flood East Zone as delineated using the Florida DOT 2008 Hydrologic Data. The Flood Hazard Areas are shown in pink on this map.
There may be comments and modifications of record and/or other documents not furnished to this surveyor or shown on the boundary survey that may affect property rights and/or land use rights of the subject property.
This Survey was performed for the sole and exclusive benefit of the entitled land person and shall not be relied upon by any other party or individual whatsoever.
Underground utilities and improvements were not located, unless shown herein.
Elevation shown herein are based on Orange County Benchmark Number 1-100-026, Altim. Control Stake in West edge of sidewalk in front of address 4557 Myrtle Bay Drive, elevation being 84.88' (NAVD-83).
Date data in field December 29, 2008

- Legend:**
- ⊙ Denotes Traverse Point
 - ⊙ Denotes 1/2" Iron Rod And Cap
 - ⊙ Denotes Wood Fence
 - ⊙ Denotes Certification of Flood
 - ⊙ Denotes Orange County Sherriff's
 - ⊙ Denotes storm manhole with curb least
 - ⊙ Denotes Area Determined and Provided by Others
 - P.B. Denotes Plat Book
 - P.G. Denotes Page

6473

Figure 1. Topographic map of site created by Allen & Company showing nine bone locales marked as shaded areas.

College of Medicine

Department of Pathology, Immunology and Laboratory Medicine
Forensic Toxicology Laboratory

4800 S.W. 35th Drive
Gainesville, FL 32608
352-265-0680 x72001
352-265-9904 Fax

May 15, 2009

Jan C. Garavaglia, M.D.
District Nine Medical Examiner Office
1401 Lucerne Terrace
Orlando, FL 32806

Re: Skeletal Remains Unidentified; ME 2008-001567

Dear Dr. Garavaglia:

Thank you for the opportunity to consult with you regarding the District Nine Medical Examiner Case 2008-001567 - Skeletal Remains Unidentified. On December 18, 2008, I obtained specimens from the following sites from ME 2008-001567 under your supervision –

1. Left femur
2. Marrow from left femur
3. Saline wash (first) of cranial cavity
4. Saline wash (second) of cranial cavity
5. Strands of hair
6. Matted hair
7. Soil from matted hair

The specimens were subjected to a variety of routine laboratory tests in the University of Florida Forensic Toxicology Laboratory to determine the absence or presence of volatiles and prescription, over-the-counter, and illicit drugs. The techniques utilized included immunoassay, gas chromatography and gas chromatography-mass spectrometry.

More specifically, the results are as follows –

1. Volatiles were not detected in aliquots of bone, bone marrow, hair, and soil by automated headspace gas chromatography-mass spectrometry. This includes, but is not limited to, chloroform, ethanol, acetone, isopropanol, methanol and toluene. Products of decomposition were not detected.

2. Prescription, over-the-counter, and illicit drugs were not detected in aliquots of bone, bone marrow and cranial cavity washes by immunoassay, gas chromatography and gas chromatography-mass spectrometry.
3. Alprazolam was not detected in aliquots of bone, bone marrow and cranial cavity washes by gas chromatography-mass spectrometry.

In summary, volatiles and drugs were not detected in the specimens obtained from the remains of Skeletal Remains Unidentified; ME 2008-001567. These results do not rule-out the decedent's prior use and/or exposure to volatiles and/or drugs.

Sincerely,



Bruce A. Goldberger, Ph.D., DABFT
Professor and Director of Toxicology

Re. R08-02820